

Epithelioid angiomyolipoma of the kidney: a rare variant of angiomyolipoma

Lubna M. Azzouz and Laila S. Elbarghati

Department of Pathology, Faculty of Medicine, University of Tripoli, Tripoli, Libya

Correspondence to Laila S. Elbarghati

Abstract: 39-year-old Libyan female presented with history of abdominal pain with left renal mass and retroperitoneal hematoma for two months. The tumor was epithelioid angiomyolipoma (EMLA). So far, only a small number of EAMLs have been reported, here we present the first case diagnosed in the Tripoli Medical Center. She was referred to medical oncology for discussion of surveillance versus potential adjuvant therapy.

Key words: kidney, epithelioid angiomyolipoma (EAML), malignant potential

Introduction

Angiomyolipoma (AML) of the kidney is a rare benign tumor that comprises 3.0% of all renal tumors (1). It is long believed to be a benign hamartoma, now, they are recognized as neoplasms of clonal origin, showing clonal chromosomal aberrations and originating from a common progenitor cell, the perivascular epithelioid cell (PEC), hence the name PEComa (2).

Epithelioid angiomyolipoma (EAML) is a mesenchymal tumor related to classic angiomyolipoma, first described in 1996 by Mai and others (3) as composed of perivascular epithelioid, vascular, adipose, and smooth muscle cells involving the kidneys, liver and other organs. This rare subtype of AML is potentially malignant and may exhibit aggressive biological behavior, including recurrence, difficult histological characterization, metastasis and poor prognosis (4, 5).

Case report

A 39-year old Libyan female admitted to Tripoli Medical Center with a history of abdominal pain for two months. Patient is hypertensive for one year on salt restricted diet. She had previous history of admission for ten days because of generalized abdominal pain where ultrasound showed retroperitoneal hematoma and treated by drainage. Patient received five units of blood and admitted to Intensive Care Unit (ICU). Abdominal examination showed tenderness in the right lower abdomen. Other systemic examinations were normal. There was no lymphadenopathy or ascitis. All her haematological investigations, BUN and serum creatinine were normal. Urine sediment showed many red blood cells, mucus and WBC. Ultrasound kidney showed blood in the abdominal cavity (perinephric hematoma with left renal mass) patient admitted in ICU for 12 days and

received 10 units of blood. Computed tomography (CT) scan showed left preinephric hematoma with suspicious lesion in the lower pole of the kidney. Magnetic resonance imaging (MRI) showed 3 cm rounded mass near the inferior pole of the left kidney, evidence of capsular invasion and preinephric hematoma (Fig. 1).

The radiological findings are consistent with either renal cell carcinoma or angiomyolipoma. Left kidney showed normal renal capsule, perirenal fat and vessels with a mass ifreception finding occupying the lower part. Postoperative period passed smoothly without complications. On gross examination fresh partial nephrectomy specimen received. It was irregular grayish tan to yellow measured 7 x 4 cm with perinephric fat. Cut surface shows rounded haemorrhagic mass measured 3 x 2 cm in the lower pole of the kidney. Microscopically, sections reveals kidney parenchyma with a mesenchymal tumor composed in most areas of sheets of rounded to polygonal cells with eosinophilic granular to amphi-

philic and clear cytoplasm. The tumor cells show nuclear pleomorphism with multinucleated ganglion like cells which are frequently seen throughout.

There are areas of hemorrhage with foamy histocytes and foreign body reaction (Fig. 2). No observed mitotic figures seen however the proliferation index was high with utilization of immunostain. In a focal area the tumor shows an intimate admixture of smooth muscle cells with thick walled blood vessels lacking the internal elastic lamina along with mature adipose tissue. There is a safe margin of renal parenchyma which is free from tumor invasion however; capsular invasion with extension into preinephric fat is seen.

Immunohistochemical markers reveal positivity of the melanocytic marker (Mart-1/Melan A), smooth muscle actin (α SMA), Vimentin, (Fig. 3) EMA and Ki-67 (Figures not shown). The features are consistent with epithelioid angiomyolipoma with capsular and perinephric fat invasion.

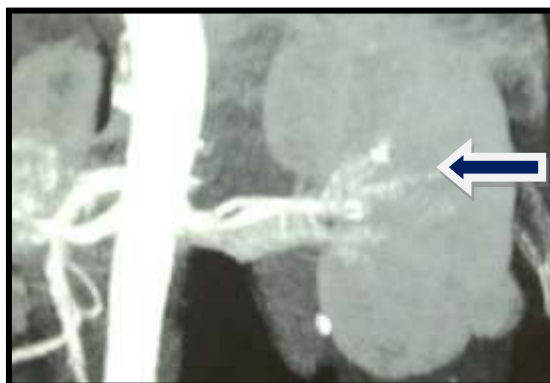


Figure 1: CT-scan shows 3cm rounded mass in the lower pole of left kidney

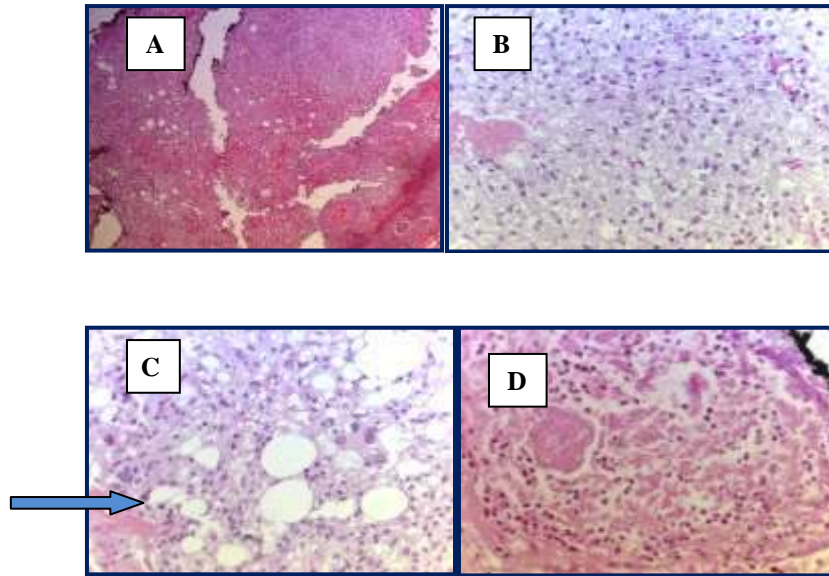


Figure 2: Histological features. A: Angiomyolipoma with 3 classic elements (thick walled blood vessels, smooth muscle cells & fatty tissue). B: Epithelioid cells (sheets of rounded to polygonal cells with eosinophilic granular to amphophilic and clear cytoplasm). C: The tumor cells show nuclear pleomorphism with multinucleated ganglion-like cells (arrow). D: In the central area of the neoplasm necrosis was observed (H & E stain) (A x 5: B, C & D x 40)

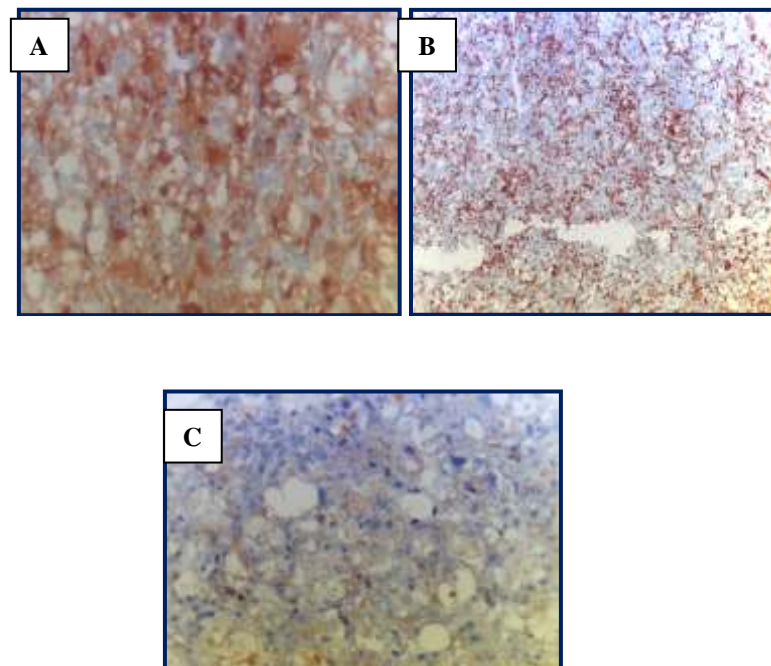


Figure 3: Immunostaining for angiomyolipoma. A: Tumor cells show strong & diffuse Mart-1/Melan A staining. B: Tumor cells show strong Vimentin staining. C: Tumor cells show moderate smooth muscle actin (α SMA) staining in spindle areas. (A, C x 40: B x 10 Immunoperoxidase).

Discussion

The usual or classic renal angiomyolipoma (AML) is a benign mesenchymal tumor composed of a variable proportion of fat, spindle and epithelioid smooth muscle cells, and abnormal thick-walled vessels (6). A number of morphologic variants of AML have been described in literature that include epithelioid, oncocytic, fat-predominant, smooth muscle-predominant, and AML with epithelial cysts (1, 7, 8). The 2004 World Health Organization (WHO) Classification of Renal Neoplasms defines epithelioid-AML as a potentially malignant mesenchymal neoplasm, characterized by a proliferation of predominantly epithelioid cells (9) with approximately half of patients experiencing metastases, in contrast to the classic AML that is considered benign. Malignant transformation has been rarely reported in which p53 mutation play an important role in such transformation (10, 11) Epithelioid angiomyolipoma is frequently associated with tuberous sclerosis (TSC) in 50% of cases (12, 13) however; this case has no family history of tuberous sclerosis. According to Aydin *et al.*, the ratio of occurrence of EAML in females versus males is 6.5: 1.0 and they are younger than classical AML patients (38.6 years versus 52.3 years) as in our case. The mean size of an EAML is larger than that of a classical AML, in Tsukada *et al.*'s study the average size of all eight EAMLs was 7.4 cm. The larger size of EAML might be related to their malignant potential. However, in this case, the diameter was only 3 cm.

Epithelioid angiomyolipoma often resemble renal cell carcinoma radiographically as in this case. The presence of fat is specific for the diagnosis of AMLE (16). The kidney is the most common primary site for AML, although the involvement of extrarenal sites including liver and retroperitoneum has occasionally been described (17).

Histologically, it is well-characterized triphasic tumors composed of fatty tissue, blood vessels and smooth muscle (18). It is composed of polygonal large-sized tumor cells arranged in an epithelioid manner. Differential diagnosis from renal cell carcinoma (RCC) is often challenging because of its epithelioid morphology and the melanosome marker HMB-45 is helpful for its identification (19). PEcoma' encompasses a group of related mesenchymal tumours containing PEC, these tumours included renal and extra-renal angiomyolipoma (2).

Due to the rarity of these neoplasms, definite criteria of malignancy have not yet been established. Brimo and his colleagues 2010 developed a predictive model of 4 atypical features in epithelioid angiomyolipoma that included: (1) $\geq 70\%$ atypical epithelioid cells, (2) \geq mitotic figures per 10 hpf, (3) atypical mitotic figures, and (4) necrosis; the presence of 3 or all of the features was highly predictive of malignant behaviour. While Nese *et al.*, proposed five features that include (1) Tuberous sclerosis, (2) tumour size (7cm), (3) with carcinoma like growth, and (4) involvement of perinephric fat and/or renal vein, and (5) necrosis. They considered lowrisk group (0 - 1 of the

above parameters); intermediate-risk group (2-3 of the above parameters); high-risk group (4-5 of the above parameters). One key feature, necrosis, was shared in these two predictive models. Definite diagnosis and tumor resection at an early stage could be important in the management of patients with EAML. The management of EAML depends on the size of the tumor, the radiological features, and the histological appearance. As the tumor mimics RCC on imaging studies, most patients with EAML are

treated with surgical excision. Actually, surgical excision is the gold standard treatment for EAML due to its malignant potential. Partial nephrectomy should be reserved for tumors \leq 4 cm in size. For tumors $>$ 4 cm, radical nephrectomy should be performed (21). In conclusion, this is one case of EAML, reported worldwide. According to presence of some fettered of malignancy it may be potentially malignant.

References

1. L'Hostis H, Deminiere C, Ferriere JM and Coindre JM (1999) Renal angiomyolipoma: a clinicopathologic, immunohistochemical, and follow-up study of 46 cases. *Am J Surg Pathol.* 23, 9: 1011-1020.
2. Martignoni G, Pea M, Reghellin D, Zamboni G and Bonetti F (2008) PEComas: the past, the present and the future. *Virchows Arch.* 452: 119-132.
3. Mai KT, Perkins DG and Collins JP (1996) Epithelioid cell variant of renal angiomyolipoma, *Histopathology* 28, 3: 277-280.
4. Varma S, Lacossiere K, Talwar J, Forte F and Dhar M (2008) Renal epithelioid angiomyolipoma. *J Clin Oncol.* 26, 15: 16134-1636.
5. Nese N, Martignoni G, Fletcher CD et al. (2011) Pure epithelioid PEComas (so-called epithelioid angiomyolipoma) of the kidney: A clinicopathologic study of 41 cases: detailed assessment of morphology and risk stratification. *Am J Surg Pathol.* 35, 2: 161-76.
6. Martignoni G, Amin MB. Angiomyolipoma, In: Eble JN, Sauter G, Epstein JI and Sesterhenn IA (2004) (eds) WHO Classification of Tumours. Pathology and Genetics. Tumours of the Urinary System and Male Genital Organs. IARC Press: Lyon, France: 65-67.
7. Martignoni G, Pea M, Bonetti F, et al. (2002) Oncocytoma-like angiomyolipoma. A clinicopathologic and immunohistochemical study of 2 cases. *Arch Pathol Lab Med.* 126: 610-612.
8. Armah HB, Yin M, Rao UN and Parwani AV (2007) Angiomyolipoma with epithelial cyst (AMLEC): a rare but distinct variant of angiomyolipoma. *Diagnostic pathology* 2, 11: 1-5.

9. Lin WY, Chuang CK and Liao SK (2003) Renal Angiomyolipoma with Lymph Node Involvement: A Case Report and Literature Review. *Chang Gung Med J.* 26, 8: 607-609.
10. Kawaguchi K, Oda Y, Nakanishi K et al. (2002) Malignant transformation of renal angiomyolipoma: a case report. *Am J Surg Pathol.* 26, 4: 523-9.
11. Li J, Zhu M and Wang YL (2012) Malignant epithelioid angiomyolipoma of the kidney with pulmonary metastases and p53 gene mutation. *World Journal of Surgical Oncology* 10: 213-217.
12. Neumann HP, Schwarzkopf G and Henske EP (1998) Renal angiomyolipomas, cysts, and cancer in tuberous sclerosis complex. *Semin Pediatr Neurol.* 5, 4: 269-275.
13. Baisakh M (2011) Malignant Epithelioid Angiomyolipoma of Kidney in a Tuberous Sclerosis Patient: A Case Report. *Austral asian journal of Cancer* 10: 33-36.
14. Aydin H, Magi-Galluzzi C, Lane BR et al. (2009) Renal angiomyolipoma: clinicopathologic study of 194 cases with emphasis on the epithelioid histology and tuberous sclerosis association. *Am J Surg Pathol.* 33, 2: 289-97.
15. Tsukada J, Jinzaki M, Yao M et al. (2013) Epithelioid angiomyolipoma of the kidney: radiological imaging. *Int J Urol.* 20: 1105-1111.
16. Morton AB, Alec JM, Donald HH and Steven H (1998) CT diagnosis of renal angiomyolipoma: the importance of detecting small amount of fat. *AJR* 151: 497-501. Hwang HC, Hwang JI, Hung SW et al. (2008) Epithelioid Angiomyolipoma: An Overview of Five Cases with the Concept of PEComa. *Chin J Radiol.* 33: 253-260.
17. Eble JN, Amin MB and Young RH. (1997) Epithelioid angiomyolipoma of the kidney: a report of five cases with a prominent and diagnostically confusing epithelioid smooth muscle component. *Am J Surg Pathol.* 21, 10: 1123-30.
18. Bonetti F, Pea M, Martignoni G and Zamboni G (1992) PEC and sugar. *Am J Surg Pathol.* 16: 307-308.
19. Brimo F, Robinson B, Guo C et al. (2010) Renal epithelioid angiomyolipoma with atypia: a series of 40 cases with emphasis on clinicopathologic prognostic indicators of malignancy. *Am J Surg Pathol.* 34, 5: 715-22.
20. Grant C, Lacy J and Strup S (2013) A 22-Year-Old Female with Invasive Epithelioid Angiomyolipoma and Tumor Thrombus into the Inferior Vena Cava: Case Report and Literature Review. *Case Reports in Urology* Article ID 730369.