

Libyan study of 649 cases of Helicobacter-negative gastritis: a distinct entity

Elbarghati L, & Azzouz L.

Department of Pathology, Medical School, Tripoli University, Tripoli, Libya

correspondence: Dr. Laila Elbarghati Dept of Pathology, Tripoli University

Tripoli, Libya Email: bargatilaila@gmail.com

Abstract

Background: The diagnosis of Helicobacter negative gastritis made when a pathologist recognizes the characteristic features of Helicobacter gastritis, but no bacteria can be detected by special stains.

Aim: To know the local incidence and histomorphological pattern of Helicobacter negative gastritis, especially its association with intestinal metaplasia and dysplasia in gastric biopsies.

Methods: Gastric biopsy cases were selected from database of Tripoli medical center from 2002 to 2008. The biopsies were assessed for the parameters as per revised Sydney System. The age, gender and the microscopic findings in the gastric biopsies were tabulated and analysed.

Conclusion: Based on these results, Helicobacter negative gastritis is a common disease with the progression of atrophy, metaplasia and dysplasia that deserve further investigation.

Key words: Helicobacter negative gastritis, Helicobacter positive gastritis

Introduction

Gastritis typically presents as inflammation of the mucosal lining of the stomach, which can subsequently lead to the development of ulcers. The dominant etiology of gastritis worldwide has been thought to be Helicobacter pylori infection, which is also known to increase the risk of non-cardia gastric cancer by six to eightfold [1].

When a pathologist recognizes the characteristic features of Helicobacter gastritis, but no bacteria can be detected by special stains (modified Giemsa stains, silver stains, and variations on the toluidine blue stains), the diagnosis of Helicobacter negative gastritis is made. More accurate investigation for Helicobacter is The HpSA test which is a rapid, simple,

and noninvasive test for monitoring therapy. FISH is an accurate, rapid, cost-effective, The absence of bacteria expected has frequently been, assumed to represent false negative results. Explanations include sampling error, recent use of antibiotics that suppressed the infection but not the inflammation, and use of protein pump inhibitor (PPI) that decreased the numbers of bacteria and shifted their populations from the antrum to the corpus [3]. However, emerging data point to the distinct entity of Helicobacter negative gastritis.

Methods

We selected all cases of gastric biopsies from database of department of anatomical pathology, Tripoli Medical centre, the hospital attached to Tripoli University Medical Sciences, referred during January 2002 to December 2008. This retrospective review consists of only those patients with no Helicobacter pylori bacteria in their gastric endoscopic biopsies, and presented with clinical features of gastritis. Gastric biopsies were paraffin embedded, sectioned

Results

and easy-to-use test for Helicobacter detection [2].

Of interest, a recent study of patients in clinical trials with erosive esophagitis reported that between 75 and 90% of Helicobacter negative subjects had gastritis [4]. Similarly, 56–69% of Helicobacter negative subjects enrolled in clinical trials with functional dyspepsia or nonerosive gastroesophageal reflux were reported to have gastritis [5].

at 4 µm and stained with haematoxylin and eosin, then scored semiquantitatively according to the Sydney classification [6]. The following histological features were examined on each slide: type of gastritis, density of inflammation, eosinophil count, lymphoid aggregates, intestinal metaplasia and dysplasia. The age, gender, presence, site of ulcer and the microscopic findings in the gastric biopsies were tabulated and analysed.

A total of 649 out of 1256 cases of Helicobacter negative gastric biopsies were reported during seven year period between 2002 to 2008.

The age & sex distribution

There was 374 male (57.6%) & 275 female (42.4%). In male the maximum cases were seen in 8th decade (25.4%) and in female too, the maximum cases were seen in 8th decade (19.6%). Minimum age the endoscopic gastric biopsy taken was a boy with 10 years old and the maximum age was a female with 89 years old (Chart 1).

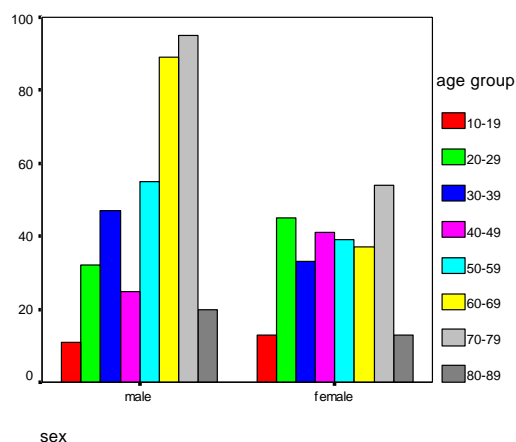


Chart 1: The age and sex distribution in helicobacter negative gastritis

The presence of ulcer and the ulcer site

There were 270 cases (41.6%) of gastritis with ulcer and 379 (58.4%) without ulcer (Chart 2). There was 16 cases of ulcer in body & 95 cases in antrum and 159 cases (58.9%) the information about site was not mentioned. There were no cases with perforation of ulcer. The ulcer size was varied from 0.5-2.0 cm in maximum dimension.

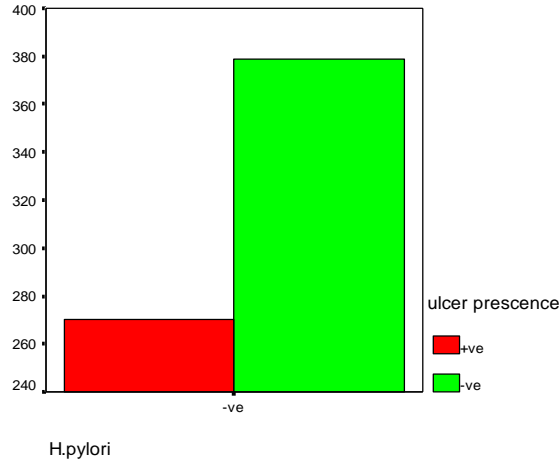


Chart 2: The presence of ulcer in helicobacter negative gastritis.

The type of gastritis

The majority of cases are of non-atrophic gastritis, which was noted in 556 (85.7%) cases. Atrophic gastritis was found in 93 cases (14.3%) (Chart 3).

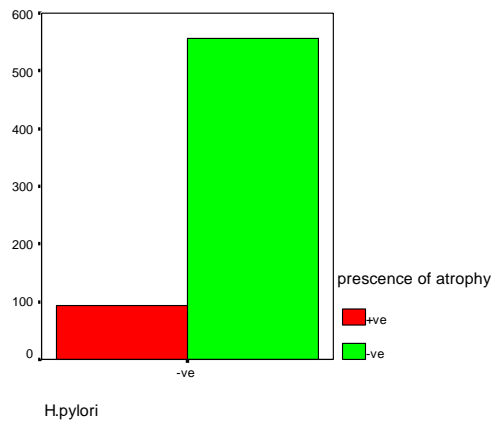


Chart 3: The presence of atrophy in helicobacter negative gastritis.

The density of inflammation

There was 136 cases (21%) mild inflammation & 230 cases (35.4%) of moderate inflammation & 283 cases (43.6%) of severe inflammation (Chart 4). The inflammatory cells were mainly lymphocytes & plasma cells and polymorphonuclear infiltrate in active inflammation (Figure 1).

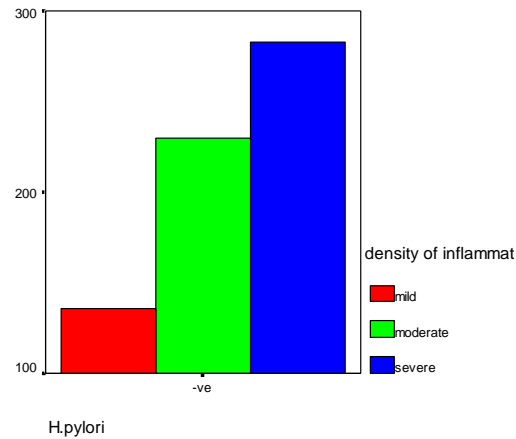


Chart 4: The density of inflammation in helicobacter negative gastritis.

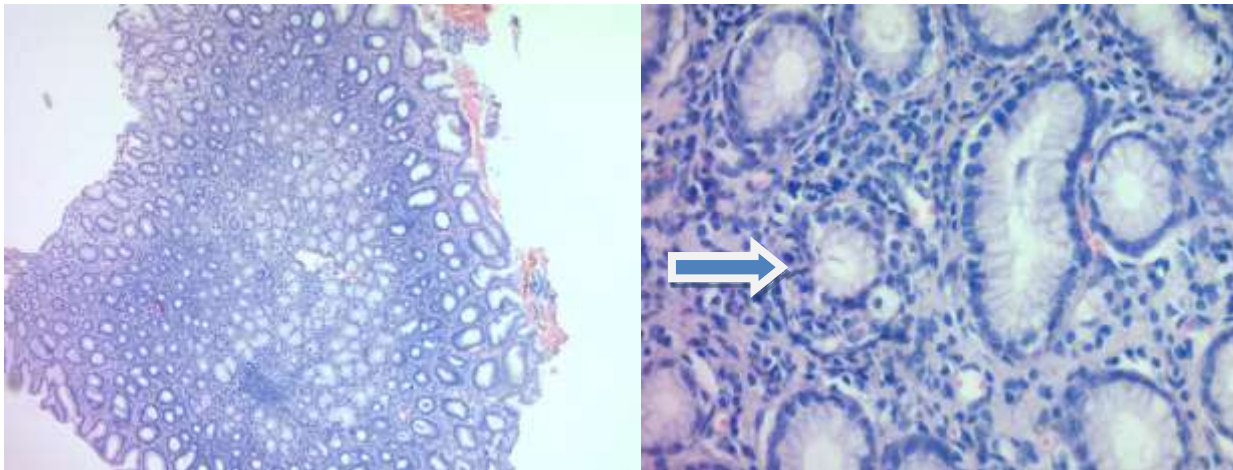


Figure 1: Photomicrograph reveals chronic active gastritis with dense inflammatory cells (x5 & x10 power) (H & E stain).

Eosinophil count & lymphoid aggregate density

Eosinophil infiltrate were noted in 28 biopsies (4.3 %). Occasional eosinophils were found in 5 cases, few eosinophils found in 9 cases & many eosinophils found in 14 cases whereas the

majority was negative for eosinophils 621 cases (95.7%). The gastric biopsies of 221 cases (34.1%) revealed lymphoid aggregates (Figure 2). Occasional lymphoid aggregate was found in 14 cases (6.3%), few lymphoid aggregate in 67 cases (30.3%), many lymphoid aggregate was found in 140 cases (63.3%) (Chart 5).

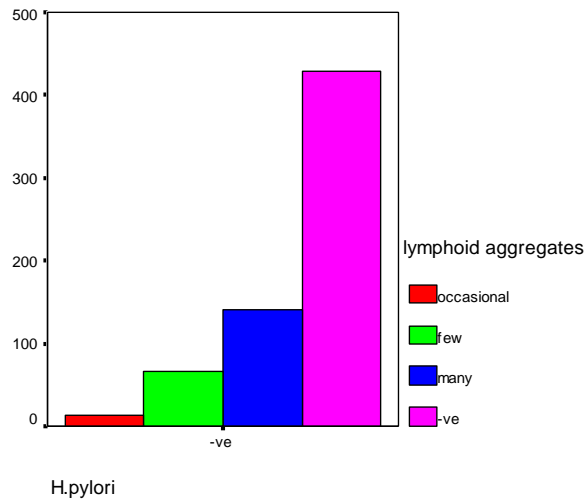


Chart 5: The density of lymphoid aggregate in helicobacter negative gastritis.

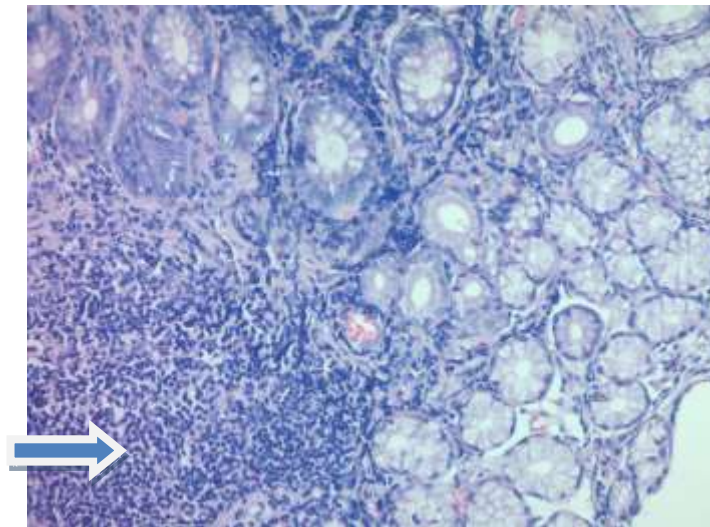


Figure 2: Photomicrograph reveals lymphoid aggregate (x40 power) (H & E stain).

The presence of intestinal metaplasia in helicobacter negative gastritis

87 cases (13.4%) showed intestinal metaplasia. Incomplete metaplasia was found in 75 cases (86.2%) whereas complete metaplasia was detected in 12 cases only (13.8%) & 562 cases (86.6%) was negative (Chart 6). One case of metaplasia was in the body, 15 cases was in the antrum & 71 cases the site was not mentioned. 19 cases of metaplasia was associated with atrophic gastritis and 68 with nonatrophic gastritis.

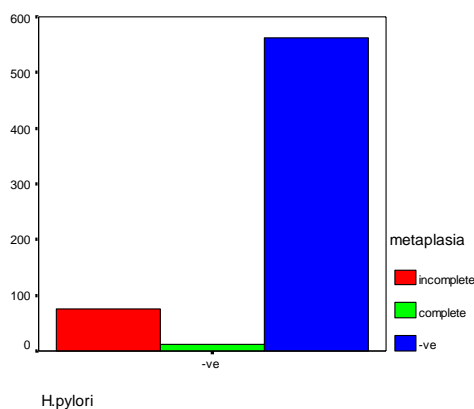


Chart 6: Intestinal metaplasia in helicobacter negative gastritis.

The presence of dysplasia in helicobacter gastritis

Twenty nine (4.5%) of gastritis cases showed gastric dysplasia. Low grade dysplasia was found in 22 cases (75.9%) and high grade dysplasia was found in seven cases only (24.1%). Among these, 2 cases of low grade dysplasia and 4 cases of high grade showed associated incomplete metaplasia (data not shown).

Discussion

Gastritis is typically defined based on histologic examination of gastric mucosal biopsies. In this study, we found that Helicobacter negative gastritis is 51.7% in 607 gastric biopsies compare to Helicobacter positive gastritis 48.3% [7]. The incidence is common in male than female with higher percentage among old

age (eighth decade) 25.4% & 19.6% in both sexes respectively, with low percentage among children, such findings correlate with other studies [8,9].

The density of inflammation is vary from mild, moderate to severe inflammation with chronic inflammatory cell infiltrate of lymphocyt, plasma cells and

polymorphonuclear infiltrate in active inflammation. The severe inflammation was found in 43.6% of cases however atrophic gastritis was present in 14.3% only (antrum) and ulcer in 41.6%. Kiichi & his coworkers investigate the extent of inflammation and atrophy in the stomach of Helicobacter positive and negative patients with chronic gastritis by endoscopy with biopsies from the lesser curvatures of the antrum, angulus, middle body, and the greater curvature of the middle body of the stomach was performed in 59 patients with histologically confirmed chronic gastritis, they found that the severity of acute and chronic inflammation at the greater curvature of the body increased with the extension of atrophic gastritis, in Helicobacter negative patients. On the other pathophysiologic substrate for mucosa associated lymphoid tissue-lymphoma [13]. Our results are in accordance with a study that also detected lymphoid follicles in almost half of cases with Helicobacter negative gastritis and idiopathic gastritis, [14,15], but are not in accordance with two more recent studies which reported that lymphoid follicles are relatively rare

hand Helicobacter negative gastritis was frequently mild, focal, and chronic and anatomically the antrum was uniquely prone to Helicobacter negative gastritis as compared to other types of gastritis [11]. This confirmed by the fact that PPIs alter the gastric acid environment and induces shifts in the Helicobacter populations within the stomach, usually reducing the bacterial burden in the antrum while increasing the inflammation in the corpus [12]. In addition, we demonstrated lymphoid aggregate in gastric biopsies of 221 cases (34.1%) this suggest that lymphoid follicles are a feature of Helicobacter negative gastritis. However, this feature is characteristic of Helicobacter pylori infection that promotes immunological response and represents the (prevalence of 4.1% in Houston, USA [16] or 14% in Tunis, Tunisia in Helicobacter negative gastritis [17].

Our results also showed intestinal metaplasia in 13.4% of patient with Helicobacter negative gastritis and 9.2% of Helicobacter positive gastritis [7] in contrast study done Genta & his colleagues [9] on 895 cases in which Intestinal metaplasia was found in

13.0% of patients with Helicobacter positive gastritis and in 6.1% of those with Helicobacter negative gastritis. Dysplasia was found in 4.5% of cases with the majority was low grade dysplasia, five cases showed associated incomplete metaplasia where as 3.5% of Helicobacter positive gastritis showed dysplastic features mainly of low grade variety [7]. This explains that dysplasia is a precursor for gastric malignancy in Helicobacter negative gastritis too. Helicobacter negative gastritis is diagnosed when no organisms are detected in a gastric mucosa with typical features of Helicobacter gastritis. A second biopsy taken, on average, 18 months after the index biopsy that showed Helicobacter negative chronic active gastritis showed detectable organisms in 7.4% of patients. Thus, a small percentage (<10%) of patients

with Helicobacter negative gastritis were likely to have a missed infection the first time. However, organisms continued to be absent in more than 90% of the patients [9]. This suggests a strong evidence that an etiology other than Helicobacter pylori infection may be responsible for the majority of cases of Helicobacter negative gastritis. Histopathology with PCR analysis, serology, urea breath test and faecal antigen test would help select a truly Helicobacter negative population. These data suggest that Helicobacter negative gastritis is a common epidemiologically entity that associated with atrophy, metaplastic & dysplastic features that deserves further investigation. Future prospective studies are needed to delineate the natural etiology, risk factors and prognosis of this poorly understood and increasing clinical disease.

References

1. Kamangar F, Dawsey SM & Blaser MJ. Opposing risks of gastric cardia and noncardia gastric adenocarcinomas associated with Helicobacter pylori seropositivity. Journal of the National Cancer Institute 200; 698: 1445–1452.
2. Aktepe OC, Çiftçi IH, Şafak B, et al. Five methods for detection of Helicobacter pylori in the Turkish population. World of Gastroenterology 2011; 17(47):5172-5176.

3. Genta RM, Schuler CM & Lash RH. Helicobacter pylori-negative chronic active gastritis: a new entity or the result of widespread acid inhibition? 2008;134 ed.: A - 125.
4. Haber MM, Hunt B, Freston JW, et al. Changes of gastric histology in patients with erosive oesophagitis receiving long-term lansoprazole maintenance therapy. *Aliment Pharmacol Ther.* 2010; 32:83–96.
5. Peura DA, Haber MM, Hunt B, et al. Helicobacter pylori-negative gastritis in erosive esophagitis, nonerosive reflux disease or functional dyspepsia patients. *J Clin Gastroenterol.* 2010; 44:180–185.
6. Ozturk S, Serinsoz E, Kuzu I, et al. The Sydney System in the assessment of gastritis: Inter-observer agreement. *The Turkish Journal of Gastroenterology* 2001; 12:36-9.
7. Elbarghati L, Azzouz L, Lakloulou I & Adiga BK. Histomorphology of Helicobacter positive gastric biopsies-Libyan study of 607 cases. *LJMR* 2016; 10 (2):1-13.
8. Nordenstedt H, David Y, Graham DY, Kramer JR, et al. Helicobacter pylori-Negative Gastritis: Prevalence and Risk factors. *Am J Gastroenterol.* 2013; 108(1):65–71.
9. Genta RM, Sonnenberg A. Helicobacter-negative gastritis: a distinct entity unrelated to Helicobacter pylori infection. *Alimentary pharmacology & therapeutics.* 2015; 41 (2): 218-226.
10. Kiichi S, Ken K, Yushi T, et al. Distribution of Inflammation and Atrophy in the Stomach of Helicobacter pylori-Positive and -Negative Patients with Chronic Gastritis. *American Journal of Gastroenterology.* 1996; 91(5): 963-969.
11. Roland BC, Lee D, Salem A et al. Prevalence and Associated Risk Factors of Helicobacter pylori Negative Gastritis. *J Gastrointest Dig Syst.* 2016; 6:(1)1-7.
12. Graham DY, Genta R, Evans DG, et al. Helicobacter pylori does not migrate from the antrum to the corpus in response to omeprazole. *Am J Gastroenterol* 1996;91:2120-2124.
13. Nakamura S, Matsumoto T, Ye H, et al. Helicobacter pylori-negative gastric mucosa-associated lymphoid tissue lymphoma. A clinicopathologic and molecular study with reference to antibiotic treatment. *Cancer.* 2006;107(12):2770–2778.
14. Zaitoun AM. The prevalence of lymphoid follicles in Helicobacter pylori associated gastritis in patients with ulcers and non-ulcer dyspepsia. *J Clin Pathol.* 1995;48(4):325–329.
15. **Broide E, Richter V, Mendlovic S, et al. Lymphoid follicles in children with Helicobacter pylori-negative gastritis *Clinical & Experimental Gastroenterology.* 2017;10:195-201.**
16. Rosas-Blum E, Tatevian N, Hashmi SS, Rhoads JM, Navarro F. Non-specific gastric inflammation in children is associated with proton pump inhibitor treatment for more than 6 weeks. *Front Pediatr.* 2014;20:2–3.
17. Mazigh Mrad S, Abidi K, Brini I, Boukthir S, Sammoud A. Nodular gastritis: an endoscopic indicator of Helicobacter pylori infection in children. *Tunis Med.* 2012;90(11):789–792.

